



PATIENT PRESENTING CLINICAL SIGNS

Smoke Marques History: Acute onset vomiting and diarrhea which has resolved.

SPECIES Physical Examination: Abdominal pain.

Feline Urinalysis: N/A.

CBC: N/A.

BREED Serum Biochemistry: N/A.

DSH Radiographic Findings: N/A.

SEX

MN

AGE

9 years

WEIGHT

10.8 #

INTERPRETED BY

Remo Lobetti, BVSc,
MMedVet (Med), PhD,
Dipl. ECVIM

ULTRASONOGRAPHIC EXAMINATION OF THE ABDOMEN

Urinary System

Full urinary bladder with normal thickness and echogenic appearance of the wall. Normal anechoic urine with no sediment or uroliths evident.

Normal trigone area, proximal urethra, and iliac blood vessels.

Normal iliac lymph nodes. Ureters not visualized.

Normal renal size, echogenic appearance, cortico-medullary differentiation, pelvis, and capsule.

Reproductive System

N/A.

Adrenal Glands

Normal shape, echogenic appearance, size, and position. Left 1 cm, right 1.3 cm.

Spleen

Normal size and echogenic appearance. Smooth homogenous parenchyma, regular capsule, and normal vasculature. No evidence of inflammatory, neoplastic, infarction, or infiltrative changes noted.

Liver

Normal size, echogenic appearance, and portal markings. No nodules or masses evident. Full gall bladder containing normal anechoic bile. Normal thickness and appearance of the gall bladder wall. Normal bile duct.

Gastrointestinal

Normal appearance of the stomach, duodenum, small intestine, ileo-cecal junction, and colon with no loss of layering, normal wall thickness and peristaltic activity, and no distension of the lumen.

INVOICE

303015

DATE

6/7/22

IMAGING PERFORMED BY

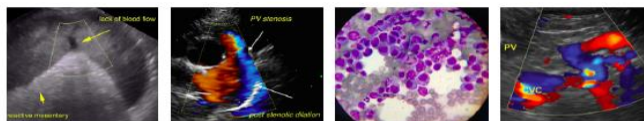
Dr Paul Kim

HOSPITAL NAME

Ridgefield Park Animal
Hospital

REFERRING VET

Dr Paul Kim



PATIENT *Pancreas*

Smoke Marques Normal size (0.6 cm) with a hypoechoogenic appearance and regular capsule. Hyperechoogenic appearance of the mesentery and fat surrounding the pancreas.

SPECIES *Free Abdomen*

Feline No mesenteric lymphadenomegaly.
No ascites.

BREED **ULTRASONOGRAPHIC FINDINGS**

DSH Primary Findings:

- Pancreatitis.

MN Secondary Findings:

- None.

AGE 9 years

WEIGHT **INTERPRETATION OF THE FINDINGS & FURTHER RECOMMENDATIONS**

10.8 # The appearance of the pancreas is typical for pancreatitis.

Further assessment would be fPL/PSL assay.

INTERPRETED BY

Remo Lobetti, BVSc,
MMedVet (Med), PhD,
Dipl. ECVIM

Supportive therapy would be low-fat intestinal diet and analgesics (opioids and/or NSAIDs).

IMAGING PERFORMED BY

Dr Paul Kim

HOSPITAL NAME

Ridgefield Park Animal
Hospital

REFERRING VET

Dr Paul Kim

INVOICE

303015

DATE

6/7/22



PATIENT

Smoke Marques

SPECIES

Feline

BREED

DSH

SEX

MN

AGE

9 years

WEIGHT

10.8 #

INTERPRETED BY

Remo Lobetti, BVSc,
MMedVet (Med), PhD,
Dipl. ECVIM

IMAGING PERFORMED BY

Dr Paul Kim

HOSPITAL NAME

Ridgefield Park Animal
Hospital

REFERRING VET

Dr Paul Kim

INVOICE

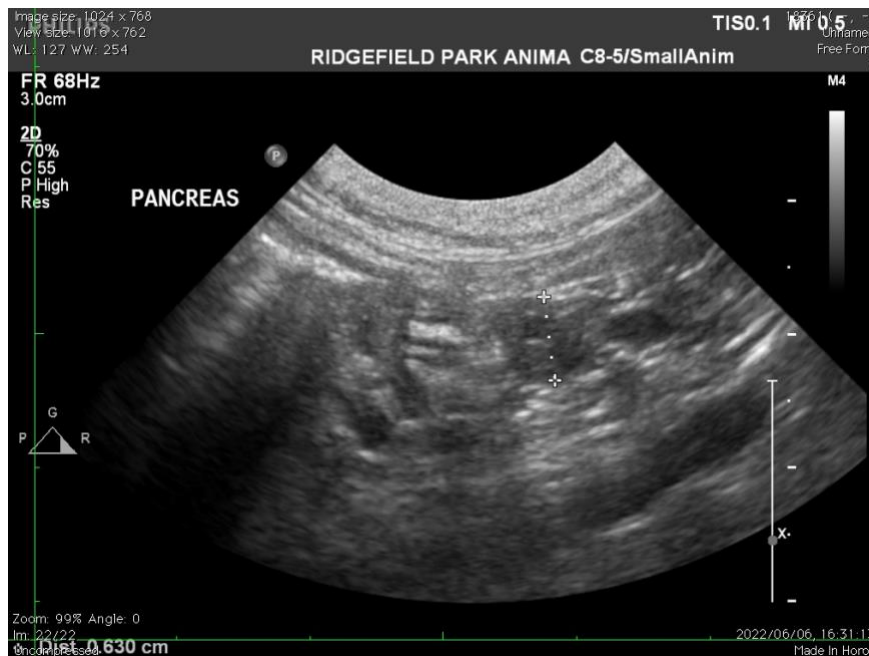303015

DATE

6/7/22

IMAGES

Pancreas



The information and recommendations provided are based on the images presented by the referring veterinarian. No evaluation can be communicated regarding pathology that was not visible in the image/video clips provided.

Thank you for this referral. If the clinical or image interpretation does not parallel your findings or if I can be of any further assistance, please contact me.

Remo Lobetti, BVSc, MMedVet (Med), PhD, Dipl. ECVIM (Internal Medicine)
rlobetti@mweb.co.za